

EMERGING TECHNOLOGY REVIEW

Gerard R. Manecke, Jr, MD

Marco Ranucci, MD

Section Editors

Transesophageal Echocardiography Simulator: A New Learning Tool

Ruma Bose, MD, Robina Matyal, MD, Peter Panzica, MD, Swaminathan Karthik, MD, Balachundar Subramaniam, MD, John Pawlowski, MD, PhD, John Mitchell, MD, and Feroze Mahmood, MD

TRANSESOPHAGEAL ECHOCARDIOGRAPHY (TEE) is a minimally invasive monitoring modality. The initial use of TEE was limited to the acquisition of images in patients with suboptimal echo windows during transthoracic echocardiography. Its role has exponentially expanded to become almost a standard of care during cardiac surgery and a valuable procedural adjunct.¹ Although the definitive direct benefit of utilization of TEE during high-risk noncardiac surgery is lacking, its role during life-threatening hemodynamic instability is well established.² However, proficiency in the performance of a TEE examination requires significant training and expertise. Training in perioperative TEE presently is available only as part of a dedicated fellowship year (cardiac anesthesia) in addition to the core anesthesia training years only at major academic centers. Furthermore, competence can be established by either successfully taking the National Board of Echocardiography Special Competence in Perioperative TEE to achieve the “testamur” status or the “board-certified” status by showing continued performance of TEE at a consistent level.

Despite the availability of clear evidence of the utility of TEE for life-threatening emergencies, only a limited number of anesthesiologists are formally trained to use it.³⁻⁵ In the past, it was possible to acquire “on-the-job training” to perform perioperative TEE and achieve board certification via the “practice experience pathway.” However, in the future, only the practitioners who have acquired dedicated TEE training during a cardiovascular fellowship will be able to achieve the board certification. It was believed that, although these training requirements were essential for an “advanced-level” training, it was essential to have a “basic-level training” to familiarize the general anesthesiologists with perioperative TEE. The American Society of Anesthesiologists/Society of Cardiovascular Anesthesiologists (ASA/SCA) recognized that this initiative has the potential to improve patient safety during general anesthe-

sia. As a result, the ASA/SCA have introduced multiple “basic echocardiography” workshops for anesthesiologists.

TRADITIONAL TEE TRAINING

Traditional TEE training is performed in the operating room (OR) during a procedure in which perioperative TEE is being performed, generally a cardiac surgical procedure. The echocardiographer is expected to recognize normal anatomic structures, appreciate abnormal structures, assess function, and quantify abnormalities to complete a standardized examination according to the guidelines.⁶ The structural 2-dimensional examination has to be supplemented with a Doppler interrogation of the relevant structures to diagnose the severity of stenosis and regurgitation. This examination has to be repeated whenever there is a significant hemodynamic change or instability (eg, weaning from cardiopulmonary bypass [CPB]).

Image Orientation

Echocardiographic anatomy is different in that it is the visualization of the intracardiac structures from the perspective of the TEE probe (ie, visualizing the heart from behind in multiple planes). The comprehensive perioperative TEE examination requires a significant “reorientation” of the echocardiographer with the intracardiac anatomy. This is because the TEE image of the heart displayed on the monitor has been manipulated (flipped upside down and left to right) to achieve a virtual cephalad to caudad view of the heart in the chest cavity (Fig 1). The image orientation can be even more confusing with vertical and oblique plane imaging. Hence, the training in TEE is associated with a substantial “learning curve” and mental reconstruction of a 3-dimensional model of the heart from multiple 2-dimensional planes.

Probe Manipulation

The acquisition of TEE images involves advancing the probe from the upper esophagus to the deep transgastric position and a combination of ante flexion, retroflexion, side-to-side manipulation, and rotation of the scan plane from 0° to 180°. Because of a beating heart and respiratory movements, the echocardiographer needs to make constant adjustments to acquire and maintain the image of interest in the center of the display. Other than the “trial-and-error” method, there is no effective mode of feedback to make appropriate adjustments to optimize the image.

From the Department of Anesthesiology, Beth Israel Deaconess Medical Center, Boston, MA.

Address reprint requests to Ruma Bose, MD, Department of Anesthesiology, Beth Israel Deaconess Medical Center, 333 Brookline Avenue, Boston, MA 02215. E-mail: rbose@bidmc.harvard.edu

© 2009 Elsevier Inc. All rights reserved.

1053-0770/09/2304-0021\$36.00/0

doi:10.1053/j.jvca.2009.01.014

Key words: transesophageal echocardiography, simulator, teaching

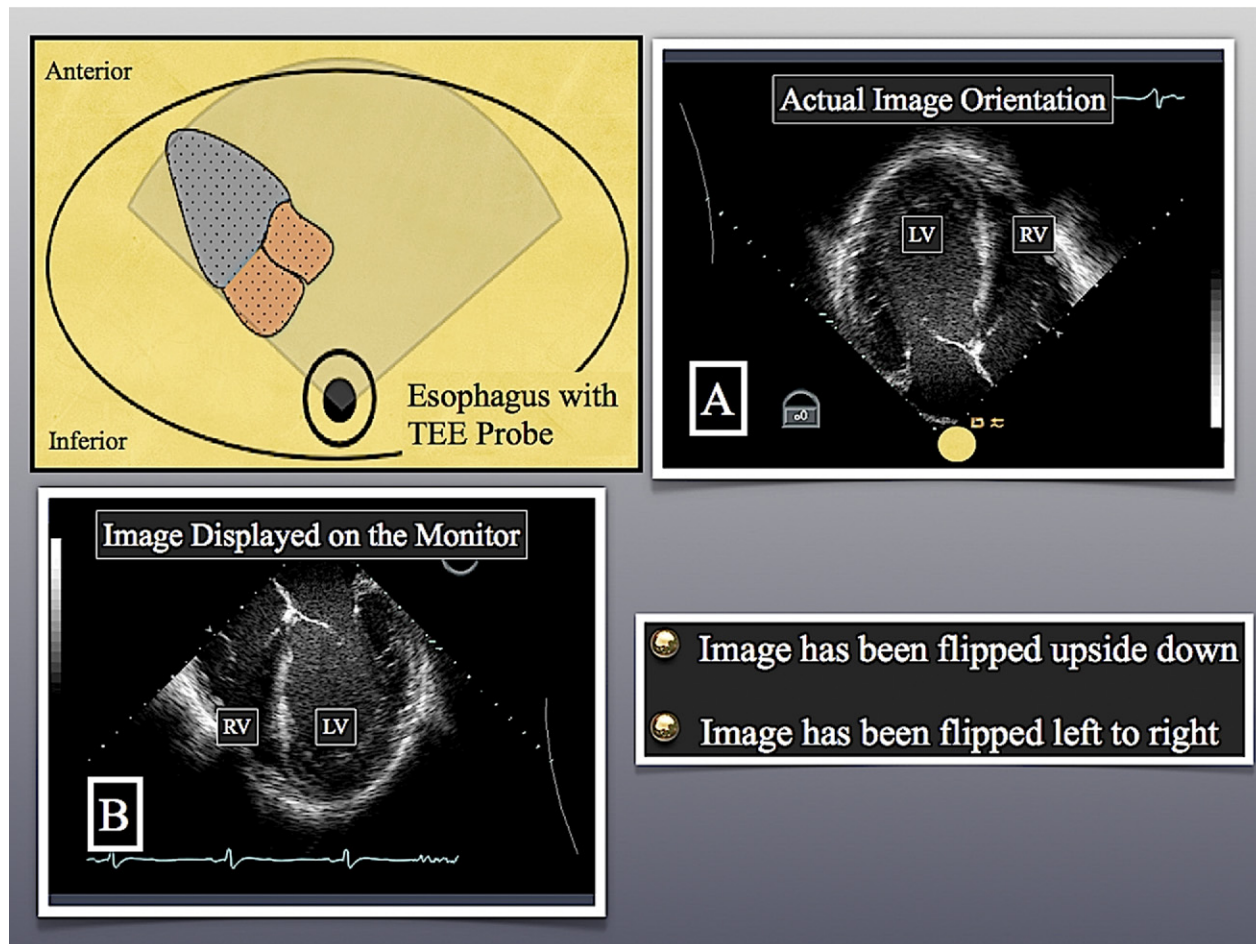


Fig 1. The orientation of the image displayed on the monitor is reversed in relation to the imaging plane or, in other words, is a mirror image of the images acquired by the interrogating beam. (Color version of figure is available online.)

Time Constraint

Another challenging aspect of TEE training is the time constraint of performing a reliable comprehensive examination as well as a focused examination of the structure of interest (eg, mitral valve and making measurements in the pre-CPB period). It takes significant training and experience to perform a comprehensive examination in a timely fashion.

TEE Training Outside the OR

The acquisition of TEE training outside the OR is limited to the attendance of continuing medical education courses, seminars, and some computer-based teaching tools to learn orientation of the probe positions and imaging planes. For the practicing anesthesiologist, there are a handful of programs that allow “observation-only” training because of regulatory requirements, and the attendees are not allowed to touch or manipulate the TEE probe in the OR. Even for residents and fellows, there is no facility/equipment to learn the basic skills and probe manipulations and appreciation of “normal” outside the OR to decrease the initial learning curve.

TEE SIMULATOR

Considering all these impediments, the TEE simulator was developed by cardiac anesthesiologists from the Heart Hospital in London, UK, in association with a graphics animation company (Glassworks, London, UK). The finished product was made available for commercial use in October 2008.

It required the digital reconstruction of an anatomically correct beating model of a normal heart (Video 1 [supplementary videos accompanying this article are available online]). Furthermore, a “digital” TEE probe was also constructed in relation to the digital heart. The probe possesses all the functions of a regular multiplane TEE probe and can scan the heart at any angle to display the external and internal anatomy of the heart (Fig 2 and Video 2). The simulator also comes with a mannequin and a realistic TEE probe, which can be used to manipulate and change the digital image (Fig 3).

Technical Specifications

The simulator consists of a Microsoft Windows–based computer (Redmond, WA). It is based on an Intel Core 2 Duo

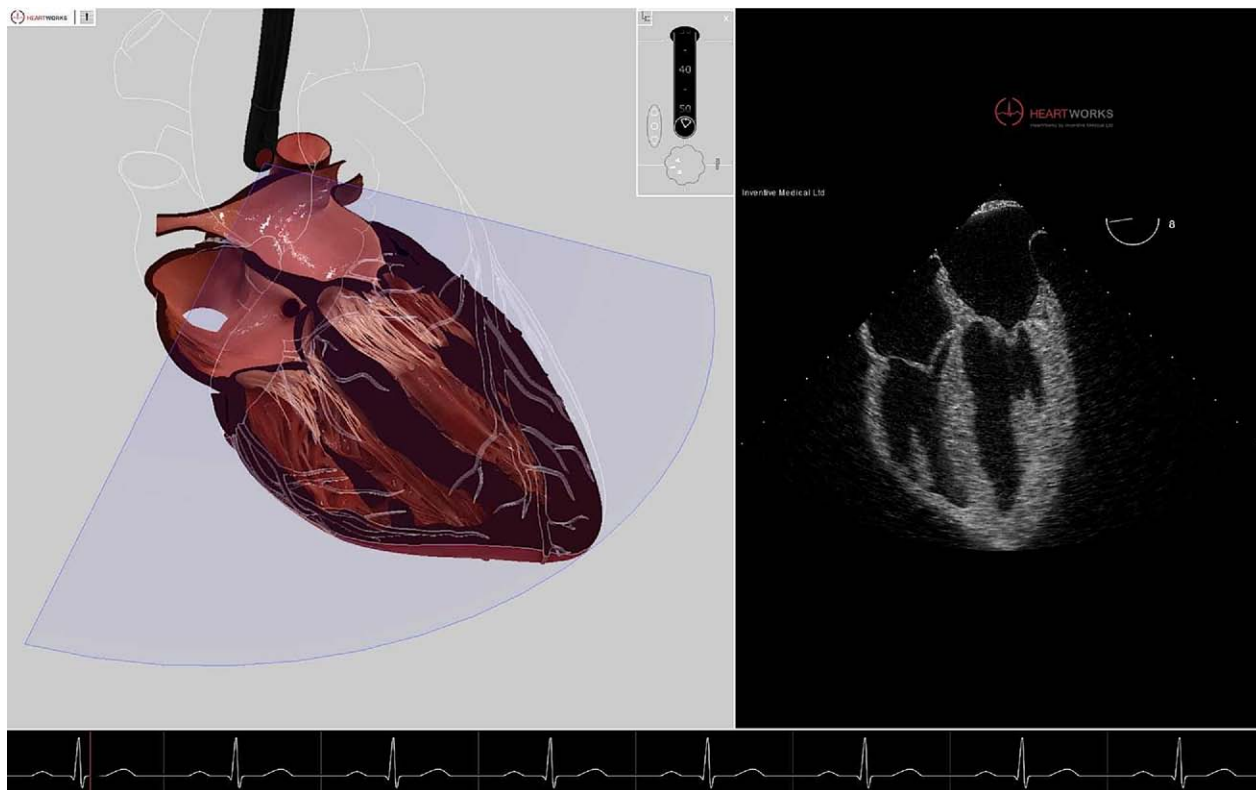


Fig 2. A midesophageal 4-chamber view and its anatomic correlate.

Processor E6750 (2.66 GHz), 2GB DDR3 1333 (2DIMMS) (Intel Corp, Santa Clara, CA), and Nvidia Quadro FX 5600 12.5 GB DDR3 PCI-E graphics card (Santa Clara, CA). The system also has a 74-GB 10,000 rpm SATA 16-MB Cache hard disk and a dual-layer DVD-RW writer. The image is displayed on a 24" LP2456 TFT High-Definition NVIDIA monitor for optimal display of graphics and motion. The computer is con-

nected to the mannequin and the TEE probe via a standard USB connector (Fig 3). The mannequin assembly holds only the positioning sensors for the TEE probe to orient the probe in space to the digital heart. The TEE probe connected to the mannequin is a standard TEE probe, with a large and small wheel for ante- and retroflexion and standard buttons for the rotation of the scan plane (Fig 3). All manual manipulations of the actual TEE probe are simultaneously performed by the digital TEE probe on the computer monitor to display the internal and the external anatomy of the heart.

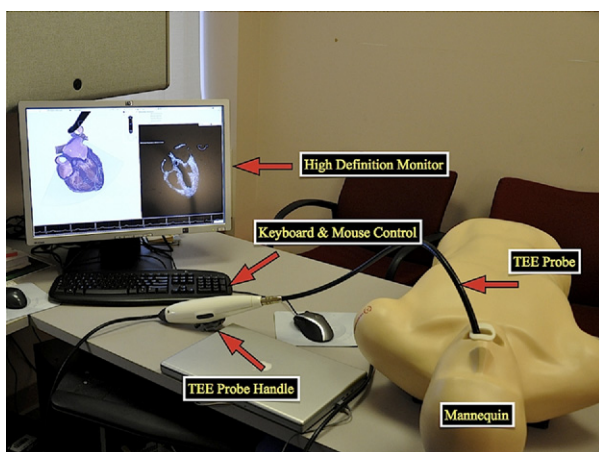


Fig 3. The transesophageal echocardiography simulator showing a high-definition monitor, TEE probe with realistic controls, a mannequin, mouse, and keyboard.

Functions

The TEE simulator can be used in a number of modes as follows.

1. Camera mode: in this mode, the viewing angle of the observer can be changed, and the heart model can be viewed from any angle with mouse control. There is a "slice plane" that can be moved forward and backward in the camera mode to slice the heart from a particular viewing angle. However, the slice plane cannot be rotated. This mode is useful to display internal cardiac anatomy from any specific perspective (Fig 4 and Video 3).
2. Manipulator mode: in this mode, both the viewing angle and the slice plane can be changed and rotated from multiple perspectives. This mode can be used to

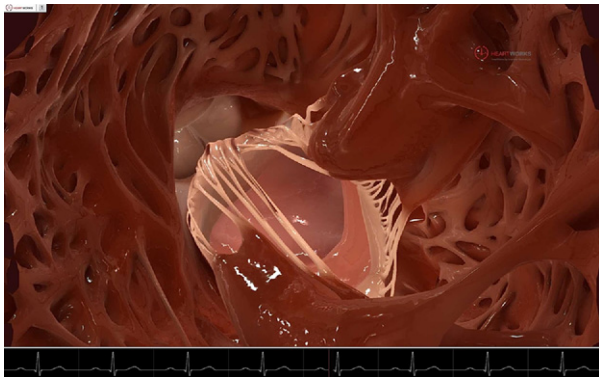


Fig 4. A realistic anatomic view of the left ventricular aspect of the mitral valve using the slice plane mode of the simulator. (Color version of figure is available online.)

slice the heart from many different angles while keeping the camera perspective constant. Both the camera and the manipulator mode only display the digital 3-dimensional anatomy of the heart.

3. Transesophageal echo mode: this is the most useful mode for virtual learning of a comprehensive intraoperative echo examination. The movements of the TEE probe can be controlled by the mouse to advance, withdraw, and ante- and retroflex the probe (Fig 5). The mouse control also can be used to rotate the scan plane from 0° to 180°. The computer renders the digital image to make it appear like an actual dynamic image as observed on a TEE machine (Video 4).

The second TEE mode of teaching is when an echocardiographer actually holds the TEE probe and manually changes its position and rotates the digital scan plane by pressing the buttons. The TEE probe manipulations are simultaneously and faithfully duplicated by the virtual TEE probe, and a rendered dynamic echocardiographic image of the heart is generated (Video 5). For the purposes of teaching and orientation, the 3-dimensional model of the heart can be displayed side by side with the echocardiographic image, or only the echocardiographic image can be displayed for testing purposes. Furthermore, with a second examiner, the TEE and the camera or manipulator mode can be used simultaneously to further enhance the image orientation and anatomic echocardiographic

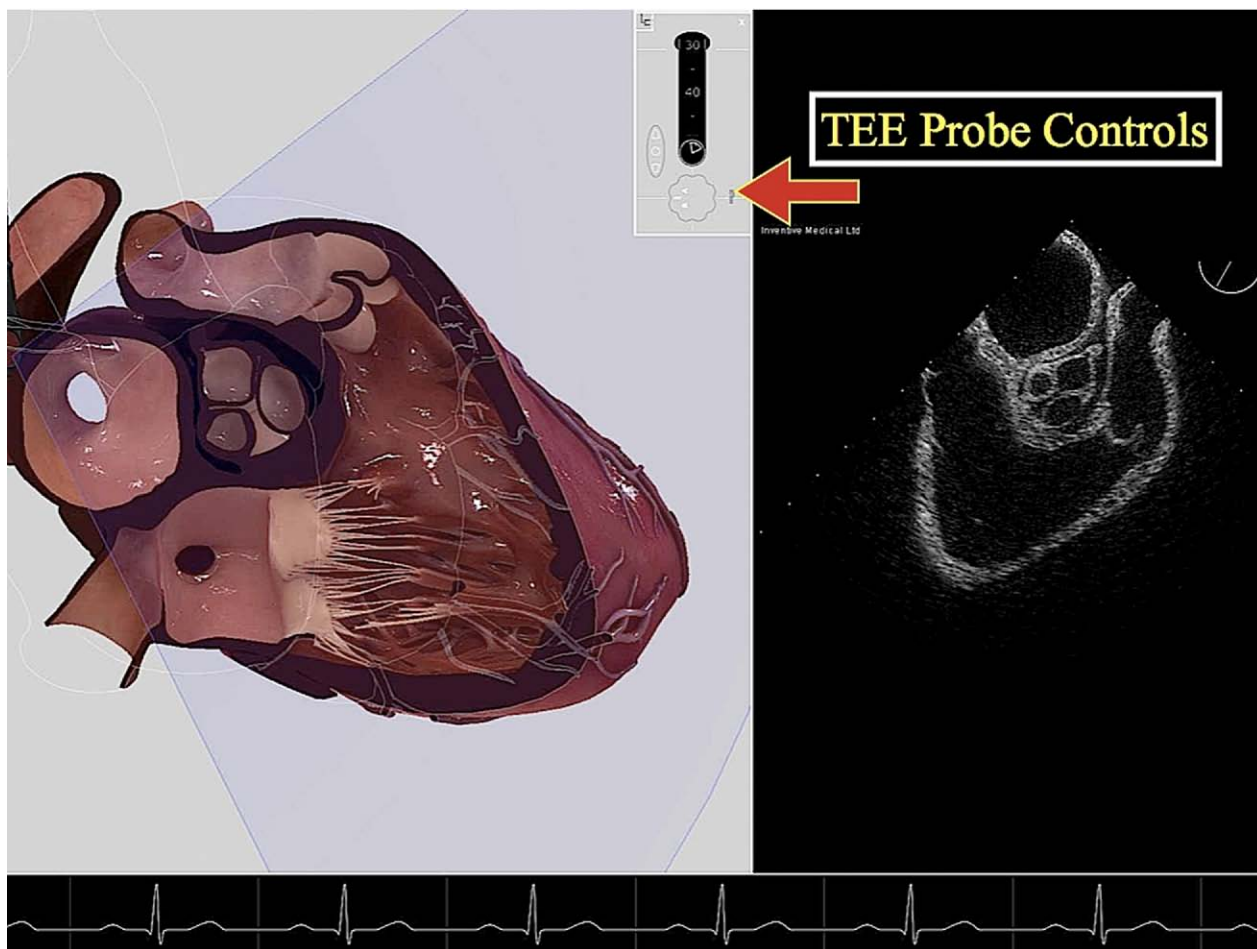


Fig 5. Shows the "TEE mode" of the simulator where image acquisition can be practiced and understood by manipulating the TEE probe, which would display the corresponding change in the imaging plane and echo image display in real time. (Color version of figure is available online.)

correlations. The probe even can be advanced to the deep transgastric position in order to acquire images (Video 6).

Additional Teaching Tools

The TEE simulator is also equipped with numerous other teaching tools. The anatomic structures (eg, mitral valve scallops) can be highlighted and linked to text explanations, which can be reviewed to further solidify the key concepts (Video 7). The software also has the capability to digitally subtract cardiac tissues in order to display the structures of interest (eg, the intracardiac valves) (Video 7). Each examiner can store his/her own specific examination steps in the memory of the computer for later review and teaching purposes.

Advantages

The TEE simulator is a robust and a powerful teaching tool. It greatly has simplified the understanding of TEE anatomy and image orientation. The concepts, which previously took weeks and months, now can be understood with a few days of practice. Above all, this all can be achieved outside the OR environment, without time pressure and performance anxiety. The understanding and comprehension of “normal” now can be achieved on a simulator so that the student can concentrate more on identifying “abnormal” anatomy and function.

The simulator also can be used to train anesthesiologists in

actual probe manipulations and image acquisition. This technology also can enable the “observation-only” programs to actually become “hands-on” training programs for TEE training. The TEE simulator has the potential to change the landscape of TEE training.

Disadvantages

The TEE simulator is an expensive technology, and its initial cost may prohibit its widespread use. However, it is available in multiple configurations, and the “base version” is significantly cheaper than the fully functional model. The present version is only a “normal” model of the heart, it does not have any Doppler capability, and the images cannot be used to make caliper measurements. Also, the system does not allow generation of still graphics or movie clips for use in presentations for teaching purposes.

CONCLUSION

In summary, the TEE simulator is a revolutionary advancement in the field of echocardiography with an enormous potential to simplify this complex process. It is going to enormously impact the way students are taught echocardiographic anatomy. The ability to visualize the intracardiac anatomy with such high resolution may expand its use beyond teaching echocardiography (eg, cardiac surgical anatomy and surgical planning).

REFERENCES

1. Mahmood F, Christie A, Matyal R: Transesophageal echocardiography and noncardiac surgery. *Semin Cardiothorac Vasc Anesth* 12:265-289, 2008
2. Practice guidelines for perioperative transesophageal echocardiography. A report by the American Society of Anesthesiologists and the Society of Cardiovascular Anesthesiologists Task Force on Transesophageal Echocardiography. *Anesthesiology* 84:986-1006, 1996
3. Jacka MJ, Cohen MM, To T, et al: The use of and preferences for the transesophageal echocardiogram and pulmonary artery catheter among cardiovascular anesthesiologists. *Anesth Analg* 94:1065-1071, 2002
4. Lambert AS, Mazer CD, Duke PC: Survey of the members of the cardiovascular section of the Canadian Anesthesiologists' Society on the use of perioperative transesophageal echocardiography—A brief report. *Can J Anaesth* 49:294-296, 2002
5. Poterack KA: Who uses transesophageal echocardiography in the operating room? *Anesth Analg* 80:454-458, 1995
6. Shanewise JS, Cheung AT, Aronson S, et al: ASE/SCA guidelines for performing a comprehensive intraoperative multi-plane transesophageal echocardiography examination: Recommendations of the American Society of Echocardiography Council for Intraoperative Echocardiography and the Society of Cardiovascular Anesthesiologists Task Force for Certification in Perioperative Transesophageal Echocardiography. *Anesth Analg* 89:870-884, 1999